

N E W S

OF THE NATIONAL ACADEMY OF SCIENCES OF THE REPUBLIC OF KAZAKHSTAN
SERIES OF BIOLOGICAL AND MEDICAL

ISSN 2224-5308

Volume 3, Number 327 (2018), 5 – 12

UDC (616-089.844 : 616.71-74) + 616-089.23

MRNTI 76.29.46

N. Batpenov¹, R. Shnattler², A. Belokobylov¹, E. Raimagambetov¹, K. Tazhin¹

¹Scientific Research Institute of Traumatology and Orthopedics, Astana, Kazakhstan,

²University Medical Center, Justus Liebig University of Giessen, Giessen, Germany.

E-mail: niitokz@mail.ru, Reinhard.Schnettler@chiru.med.uni-giessen.de, 9992259@mail.ru

APPLICATION OF FRESH-FROZEN ALLOGRAFTS IN ORTHOPEDICS

Abstract. At present, bone grafts are widely used in traumatology and orthopedics to replace bone defects, and there is no doubt that this method is effective. The basic orthopedic directions requiring the involvement of bone grafts are revision and complex endoprosthetics of large joints, oncortopedia. The requirements for the materials used are quite high, among them the following can be distinguished: the material used should not only physically fill the bone volume, but also possess osteoinductive properties, while the possibility of transmission of infectious diseases must be excluded. The ideal material that is accepted as the "gold standard" is autograft, but due to certain conditions its use is limited and various methods of allotransplantation are now being widely introduced.

Key words: bone allotransplantation, fresh-frozen allografts, endoprosthetics.

Bone transplantation is the main method of treating bone tissue defects caused by tumors, traumas, and the consequences of arthroplasty [1, 2]. The "gold standard" for plastics is naturally autografts since its osteogenic, osteoconductive and osteoinductive properties for a particular individual are perfect [3, 4]. However, for the use of autologous materials there are a number of constraints, so, in the case of bone, the amount of autograft required for implantation is much larger than the amount of possible sampling [5]. The second, but less restrictive factor is the fact that the graft harvesting is another surgical intervention with a subsequent pain syndrome, an increase in the time of intervention, and possible complications [6-8].

Currently, in connection with the increase in the proportion of orthopedic interventions of a revision nature (especially arthroplasty), when there is a deficit of bone tissue, researchers began to pay closer attention to the development of such an orthopedic industry as orthobiology. Biologists together with orthopedists study the behavior of tissues after implantation of various grafts, develop new materials for implantation, develop new methods for inducing integration processes, etc. Thus, alternative orthopedic materials of allogeneic, xenogeneic or synthetic origin are currently available to orthopedic clinicians [3, 9].

The use of allografts is a competitive alternative to autografts. The first allograft was applied in 1889 by the Scottish surgeon, who successfully compensated for the defect of the humerus with the tibial allograft in a 4-year-old boy suffering from rickets [10]. Later experience with the use of allografts expanded, which led to the appearance in the United States in 1949, the first tissue bank [11]. At present, there is a significant increase in interest in bone tissue allotransplantation, which leads to the appearance of bone banks in many countries of the world [12].

The main properties that characterize bone grafts are the following. Osteogenesis is the ability to trigger bone formation in the presence of living osteoprogenic cells, osteoblasts and stromal cells. Osteoinductivity is the ability to induce the differentiation of mesenchymal cells into cells that produce bone under the influence of growth factors. Osteoconductivity is the potential ability to provide structures through which vessels and bone-forming cells can migrate to form bone and structural integrity – the strength of the graft and its resistance to torsion and deformation, which are maximally affected by the cortical portion of the graft. Integration is the ability of the graft to integrate and become one with the host's bone and depends on osteogenesis, osteoinductivity and osteoconductivity.

All the proposed materials support bone regeneration due to osteoconduction, but allografts have a relatively high regenerative potential [4, 13].

Preparation of allografts is a complex, multi-stage processing process aimed at cleaning tissues from potential immunogenic components and preventing the transmission of infections. By the method of processing of the allogeneic bone, there are physical and physicochemical methods [14]. Physical handling allografts include world-wide heat treatment groups (the Maros Telos bone bank system), fresh frozen and cryopreserved bone [15, 16]. These materials are frozen (below $-20\text{ }^{\circ}\text{C}$) (heat-treated bone), irradiated (freshly frozen bone) or exposed to cryoprotective agents (dimethyl sulfoxide or glycerol) and stored at a temperature of about $-196\text{ }^{\circ}\text{C}$ (cryopreserved bone). In a freshly frozen and cryopreserved bone, viable cells can be found, which is even the goal for cryopreservation [15].

Some of the allogenic osteoplastic materials release cells chemically, exposing the bone to several stages of cleansing and chemical treatment (table).

Chemical agents used to purify the bone from cells of various allogeneic bone-plastic materials

Allografts	Chemical agents used
Puros Allograft, Tutoplast® Spongiosablock [17]	Hydrogen peroxide, NaOH, ethanol, acetone
DIZG-bone blocks [18]	Peracetic acid is ethanol
C + TBA-bone blocks, Maxgraft® [19]	Diethyl ether, ethanol, hydrogen peroxide
TBF-bone blocks	Ethanol, chloroform, hydrogen peroxide, sodium hypochlorite

The final drying process, which ensures the long-term storage of bone blocks at room temperature, is carried out by evaporation of acetone (Puros Allograft, Tutoplast® Spongiosablock), this type of material is referred to in the literature as solvent-doped bone allografts (SDBA) or freeze-dried (all other producers) which are often referred to in the literature as freeze-dried bone allografts (FDBA) [20, 21]. In general, all these materials are classified as mineralized bone allografts (MBA) [22].

The whole process of purification aims to create bone-plastic material that will act as an osteoconductive matrix with optimal physico-chemical characteristics without immunogenic properties. It is of fundamental importance that, after processing, allogeneic bone-plastic materials undergo a check for the preservation of physical properties and safety.

The Research Institute of Traumatology and Orthopedics has extensive experience in the use of native, fresh-frozen allografts, and the local bone bank has been operating since October 2007. When creating a bone bank, we were guided by the recommendations of the American Association of Tissue Banks (AATB). The main supplier and user of this bank is the Republican Center for Endoprosthetics at the Research Institute of Traumatology and Orthopedics.

The literature describes the high efficiency of frozen allografts [23]. The intake of freshly frozen allografts is carried out under aseptic conditions from the corpse or from the living persons (the head of the femur with joint replacement). A necessary condition is a six-month bone quarantine [24], without the need for additional bone processing, all osteoinductive proteins remain [25].

Freshly frozen bone is then available in the form of spongy, cortical-spongy or cortical granules, as well as in the form of chips. Immediately after thawing, the allograft restores the properties of fresh bone [23].

The advantages of this method include the convenience for the surgeon, reducing the operative trauma for the patient, virtually unlimited bone volume, reducing intraoperative blood loss, the absence of pain in the donor site, and reducing the time of surgery [23, 25].

One of the main concerns with the use of transplants of this group is the possibility of transmission of infectious diseases, of which the most significant HIV infection and viral hepatitis [26]. However, the instructions developed by the bone bank to select patients, store tissues, maintain documentation guarantee the safety of allogeneity [27, 28]. Another concern is the antigenicity of allogeneity, but it is proved that when the bone is frozen below -20°C , this risk is significantly reduced [8].

Man W.Y. and colleagues [29] provide information on the positive long-term (14 years) application of this type of allografts. Storage at low temperatures and compliance with the rules of freezing and thawing also reduces immunogenicity, which is due to the destruction of antigen-presenting cells in intertrabecular spaces. The main advantage of freshly frozen allografts treated, in comparison with allogeneic bone-plastic materials, is better preservation of the biological and physico-mechanical properties inherent in normal bone [30].

D.J. Costain [31] carried out a comparative study of the use of freshly frozen allotransplants. So, it turned out that this type of allografts possesses high strength characteristics, is resistant to bending, is characterized by high fatigue strength, while frost does not affect the differentiation of osteoblasts, which positively affects the processes of osseointegration. However, the authors also point to the need for further in-depth study of the use of allografts.

The process of material for allotransplantation begins with an assessment of the head of the femur by the orthopedist based on the radiographic and computed tomography (CT) data before the fence. This is done in order to elicit factors that can adversely affect the quality of the bone, for example, foci of lysis, cystic sclerotic processes and stop the procurement process at an early stage. There is an anamnesis and serological tests are performed to exclude HIV, HBV, HCV and syphilis from the donor. Only after receiving negative results of all these analyzes, fetus and further bone processing are allowed. Of the 970 we collected from 2007 to 2015, the head of the femur was suitable for use were 402 heads.

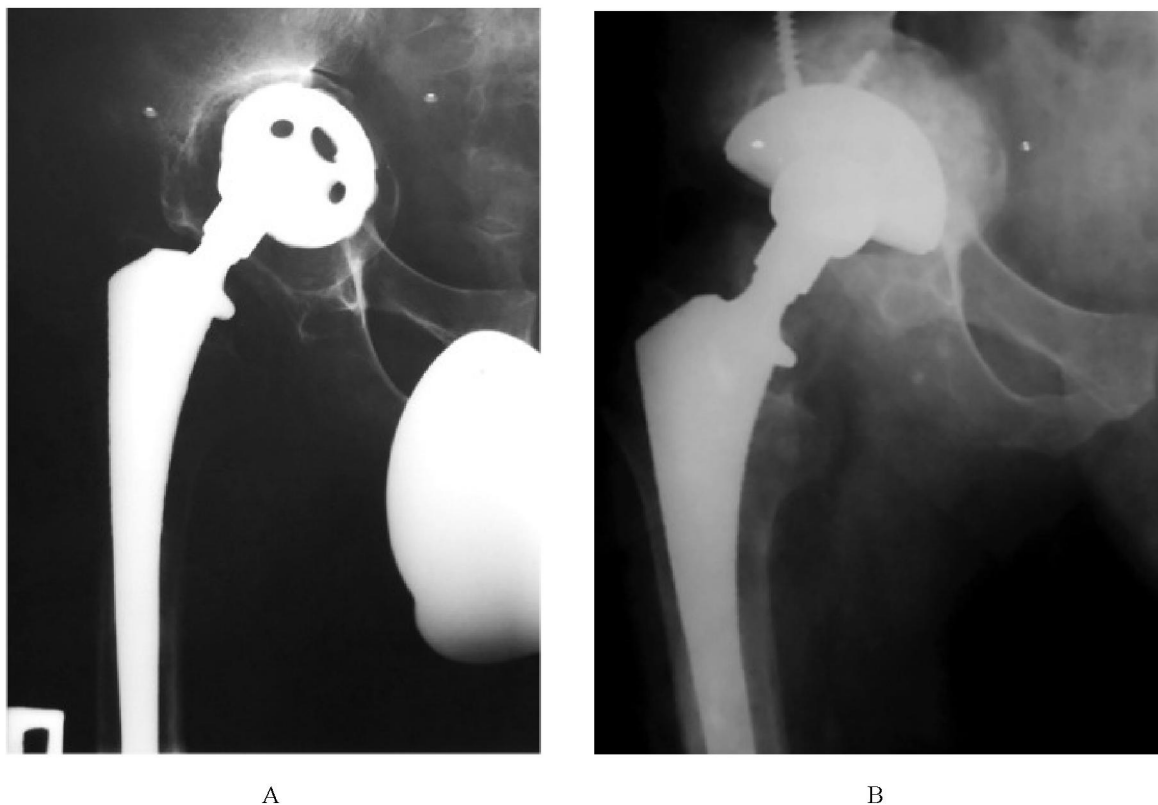
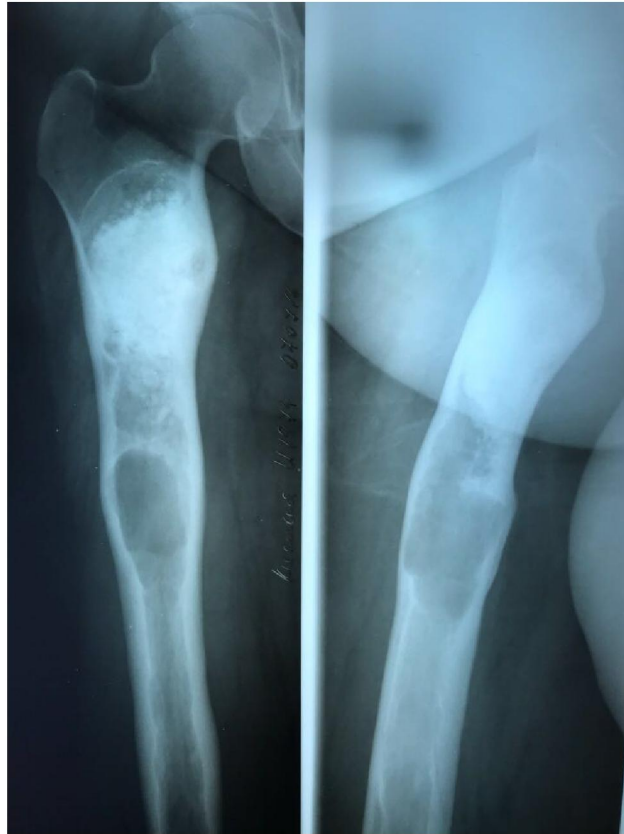

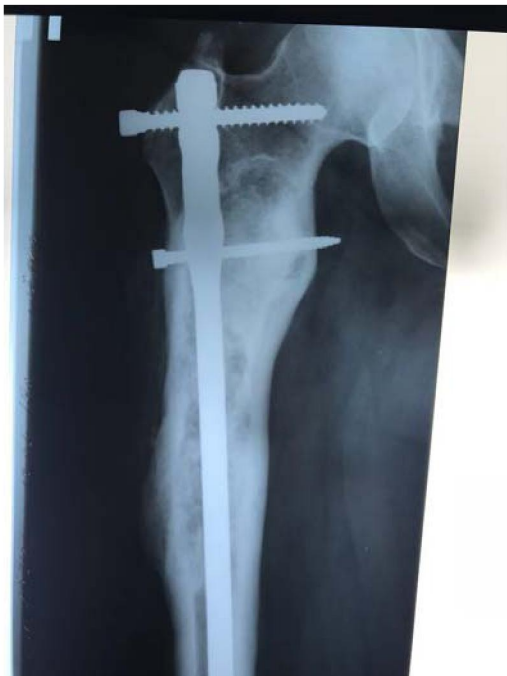Figure 1 – Clinical example.

A – aseptic instability of the acetabular component of the endoprosthesis with the central dislocation of the acetabular component of the endoprosthesis.

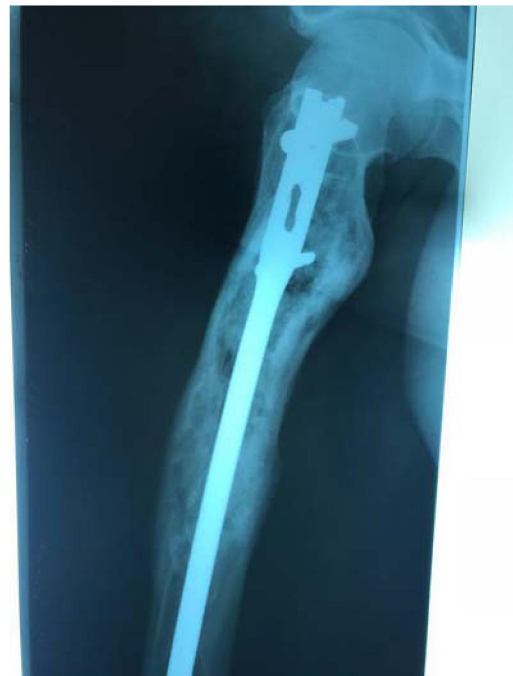B is the long-term result of revascular endoprosthetics with alloplasty of the bottom of whirlpool vapdina with freshly frozen allograft.



A



I



II

B

Figure 2 – Clinical example.

A – X-ray of the right femur in 2 projections is a giant cell tumor of the proximal femur.

B – a distant result of removing the formation of the proximal femur, the plasticity of the freshfrozen allograft, the preventive blocking osteosynthesis of the femur.

The optimal temperature for storage of tissues is not precisely defined and continues to be the subject of discussions. The temperature of -80°C , recommended by most researchers to store bone grafts, has been determined empirically. The main motivations were the inactivation of the enzymatic activity and growth of ice crystals [30]. C. Fölsch with co-authors for storage of biological osteoplastic materials for 2 years recommends a temperature of -20°C , for a longer storage it is recommended that the temperature must be -80°C [32]. The recommended cooling temperature in a cold installation is -1°C per minute [33], the optimal temperature for thawing of tissues is 45°C [34].

86.8% (349 heads) of the harvested bone was used in the revision of the hip joint (306 for the acetabulum and 43 for the plasty of the femur).

During this period, 412 operations of revision hip arthroplasty were performed on the basis of the Republican Center for Endoprosthetics, of which 213 surgeries were performed with alloplasty.

With defects of the acetabulum type IIA-B allogeneity was used in 160 cases. In 123 cases with alkalinity, cups of cementless fixation were set and in 37 cases of a cement fixation cup.

86 operations – aseptic revision, 74 – revision after installation of cement spacer and periprosthetic infection (PPI).

Figure 1 shows a clinical example of the developed aseptic instability of the acetabular component of the right hip endoprosthesis with the central dislocation of the endoprosthesis cup (figure 1A). With auditory endopretotomy, bone alloplasty of the acetabulum bottom defect was performed with a freshly frozen allograft. Separated result 2 years after the intervention (figure 1B), good allograft integration, stable acetabular component of the endoprosthesis.

Figure 2 shows a clinical example of the use of freshly frozen allografts in oncoorthopedics. A 35-year-old patient with a giant cell tumor of the proximal femur (figure 2A). In a planned order, the removal of the formation of the proximal femur, plastic with a freshfrozen allograft, preventive blocking osteosynthesis of the femur is performed. After 2 years, a positive osseointegration of the allograft was observed in the 2-projection chest radiograph (figure 2B).

Long-term results were studied in 112 patients, the average follow-up period was 49.6 months. It should be noted that this group of patients is considered one of the most intractable in modern orthopedics. Survival of acetabular components with revision was 89%. Only 12 cases (11%) required a re-audit and only 4.5% of the patients had septic instability development, while initially revision arthroplasty with bone plastic surgery in 46% of cases was performed against the background of periprosthetic infection!

At the same time, there were no cases of transmission of infectious diseases from the recipient to the donor.

Safety of materials for allogeneic bone resorption. In the past, the publication on transmission of infection and immunological responses as a result of the use of allogeneic bone negatively affected the reputation of the method. So, Buck R.E. and call. in 1989 described the first case of HIV transmission through bone plastic [35], and Conrad E.U. with a call. in 1995 [36] – the first case of transmission of hepatitis C in the negative test of the first generation in the donor. It must be understood that today such fears are valid only for the unprocessed allogeneic bone. Physico-chemically treated bone carries only hypothetically residual risks. Transmission of the infection has been documented only for allografts of untreated treatment, or untreated properly. Since the introduction of the so-called Nucltic Acid Test (NAT) in 2004, a highly sensitive and specific analysis to detect even a minimal amount of pathogen genetic material, there have been no cases of transmission of infection in human bone transplantation.

Rare descriptions of cases of allosensitization of recipients of human bone grafts are mainly associated with the use of fresh or freshly frozen bone [37-39]. The methods available to date do not allow the detection of donor-specific antibodies in recipients of physico-chemically treated allogeneic bone. It has been proved that even the incompatible system of tissue compatibility (HLA), which represents a family of proteins that allows the immune system to distinguish its own proteins from foreign ones, does not affect the integration of allogeneic bone grafts [40-42].

Treatment of infection with combined use of allografts and antibiotics. Postoperative infections after joint replacement with significant bone loss often require reconstructive surgery. Treatment of bone infection after endoprosthetics is still an urgent problem for surgeons. In recent years, the standard treatment of osteoids has been a gradual aggressive surgical treatment with massive rinsing with pulsating

jet solutions of antiseptics followed by prolonged systemic use of antibiotics, often in combination with local antibiotic therapy and subsequent surgical reconstruction of bone defects [43-45]. Nevertheless, the most important step in the treatment of bone infections is radical surgical treatment with the removal of dead bone and all foreign materials. In this vein, it is interesting to combine allogeneic bone with antibiotics for prevention or with bone marrow aspirate in order to speed up bone restructuring. For example, Y. Chang et al. [46] who established that freshly frozen allografts retain a therapeutically significant concentration of the recipient's cefazolin, which, for some time after transplantation, is released into surrounding tissues.

Conclusion. Thus, we have witnessed the effectiveness, and sometimes the inevitability, of allografts in modern traumatology and orthopedics. At the same time, the demand for allografts is projected to increase, since an increase in the number of complex orthopedic interventions, including revision joint endoprosthetics, is annually observed. Currently, a wide variety of allografts has been proposed, the experience of SRITO on the use of fresh frozen allografts indicates safety and high effectiveness, and compliance with instructions for their use makes it possible to avoid characteristic complications.

REFERENCES

- [1] Hofman A., Konrad L., Hessmann M.H., et al: The influence of bone allograft processing on osteoblast attachment and function. *J Orthop Res* 23: 846, 2005.
- [2] Hachiya Y., Sakai T., Narita Y., et al: Status of bone banks in Japan. *Transplant Proc* 31: 2032, 1999.
- [3] Finkemeier C.G. Bone-grafting and bone-graft substitutes. *J Bone Joint Surg Am.* 2002; 84-a(3): 454-464.
- [4] Giannoudis P.V., Dinopoulos H., Tsiridis E. Bone substitutes: an update. *Injury.* 2005; 36 Suppl 3:20-27.
- [5] Dimitriou R., Mataliotakis G.I., Angoules A.G., Kanakaris N.K., Giannoudis P.V. complications following autologous bone graft harvesting from the iliac crest and using the RIA: a systematic review. *Injury.* 2011; 42 Suppl 2: 3-15. doi: 10.1016/j.injury.2011.06.015.
- [6] Ilan D.I., Ladd A.L.: Bone graft substitutes. *Oper Tech Plast Reconstr Surg* 9: 151, 2003.
- [7] Williams A., Szabo R.: Bone transplantation. *Orthopedics* 27: 488, 2004.
- [8] Dodd C.A.F., Fergusson C.M., Freedman L., et al: Allograft versus autograft bone in scoliosis surgery. *J Bone Joint Surg Br* 70: 431, 1988.
- [9] Laurencin C., Khan Y., Elamin S.F. Bone graft substitutes. *Expert Rev Med Devices.* 2006; 3(1): 49-57.
- [10] De Boer H.: The history of bone grafts. *Clin Orthop Relat Res* 292, 1968.
- [11] Leslie H., Bottenfield S. Donation, banking, and transplantation of allograft tissues. *Nurs Clin North Am* 24: 891, 1989.
- [12] Albert A., Leemruse T., Druez V., et al: Are bone autografts still necessary in 2006? A three-year retrospective study of bone grafting. *Acta Orthop Belg* 72:734, 2006.
- [13] Schmitt C.M., Doering H., Schmidt T., Lutz R., Neukam F.W., Schlegel K.A. Histological results after maxillary sinus augmentation with Straumann® Boneceramic, Bio-Oss®, puros®, and autologous bone. a randomized controlled clinical trial. *Clin Oral Implants Res.* 2013; 24(5): 576-585. doi: 10.1111/j.1600-0501.2012.02431.x.
- [14] Malinin T., Temple H.T. comparison of frozen and freeze-dried particulate bone allografts. *Cryobiology.* 2007; 55(2): 167-170. doi: 10.1016/j.cryobiol.2007.05.007.
- [15] Simpson D., Kakarala G., Hampson K., Steele N., Ashton B. Viable cells survive in fresh frozen human bone allografts. *Acta Orthop.* 2007; 78(1): 26-30. doi: 10.1080/17453670610013385.
- [16] Borghetti A., Novakovitch G., Louise F., Simeone D., Fourel J. Cryopreserved cancellous bone allograft in periodontal intraosseous defects. *J Periodontol.* 1993; 64(2): 128-132. doi: 10.1902/jop.1993.64.2.128.
- [17] Schoepf Ch. The Tutoplast® process: a review of efficacy. *Zimmer Dental.* 2008; 17: 40-50.
- [18] Pruss A., Göbel U.B., Pauli G., Kao M., Seibold M., Mönig H.j., Hansen A., von Versen R. Peracetic acid-ethanol treatment of allogeneic avital bone tissue transplants – a reliable sterilization method. *Ann Transplant.* 2003; 8(2):34-42.
- [19] Osbon D.B., Lilly G.E., Thompson C.W., Jost T. Bone grafts with surface decalcified allogeneic and particulate autologous bone: report of cases. *J Oral Surg.* 1977; 35(4): 276-284.
- [20] Lee D.W., Pi S.H., Lee S.K., Kim E.C. Comparative histomorphometric analysis of extraction sockets healing implanted with bovine xenografts, irradiated cancellous allografts, and solvent-dehydrated allografts in humans. *Int J Oral Maxillofac Implants.* 2009; 24(4): 609-615.
- [21] Mellonig J.T. Freeze-dried bone allografts in periodontal reconstructive surgery. *Dent Clin North Am.* 1991; 35(3): 505-520.
- [22] Beck T.M., Mealey B.I. Histologic analysis of healing after tooth extraction with ridge preservation using mineralized human bone allograft. *J Periodontol.* 2010; 81(12): 1765-1772. doi: 10.1902/jop.2010.100286.

- [23] Hardin C. Banked bone. *Otolaryngol Clin North Am* 27: 911, 1994.
- [24] Simpson D., Kakarala G., Hampson K., et al: Viable cells survive in fresh frozen human bone allografts. *Acta Orthop* 78: 26, 2007.
- [25] Perrott D.H., Smith R.A., Kabam L.B. The use of fresh frozen allogeneic bone for maxillary and mandibular reconstruction. *Int J Oral Maxillofac Surg* 21: 260, 1992.
- [26] Gazdag A.R., Lane J.M., Glaser D., et al: Alternative to autogenous bone graft: Efficacy and indications. *J Am Acad Orthop Surg* 3: 1, 1995.
- [27] Tomford W.W., Doppelt S.H., Mankin H.J., et al: Bone bank procedures. *Clin Orthop Relat Res* 15, 1983.
- [28] Palmer S.H., Gibbons C.L.M.H., Athanasou N.A. The pathology of bone allograft. *J Bone Joint Surg Br* 81: 333, 1999.
- [29] Man W.Y., Monni T., Jenkins R., Roberts P. Post-operative infection with fresh frozen allograft: reported outcomes of a hospital-based bone bank over 14 years. *Cell Tissue Bank*. 2016; 17(2): 269-275. DOI:10.1007/s10561-016-9547-8.
- [30] Vorob'ev K.A., Bozhkova S.A., Tihilov R.M., Chernyĭ A.Zh. Sovremennyye sposoby obrabotki i sterilizacii allogennykh kostnykh tkaneĭ (obzor literatury). *Travmatologiya i ortopediya Rossii*. 2017; 23(3):134-147. DOI: 10.21823/2311-2905-2017-23-3-134-147.
- [31] Costain D.J., Crawford R.W. Fresh-frozen vs. irradiated allograft bone in orthopaedic reconstructive surgery. *Injury*. 2009; 40(12): 1260-1264. DOI: 10.1016/j.injury.2009.01.116.
- [32] Fölsch C., Mittelmeier W., Bilderbeek U., Timmesfeld N., von Garrel T., Peter Matter H. Effect of Storage Temperature on Allograft Bone. *Transfus Med Hemother*. 2012; 39(1): 36-40. DOI: 10.1159/000335647.
- [33] Parkes A.S. Factors affecting the viability of frozen ovarian tissue. *J Endocrinol*. 1958; 17(4): 337-343.
- [34] Taylor A.C. The physical state of transition in the freezing of living cells. *Ann N Y Acad Sci*. 1960; 85: 595-609.
- [35] Buck B.E., Malinin T.I., Brown M.D. Bone transplantation and human immunodeficiency virus. an estimate of risk of acquired immunodeficiency syndrome (aids). *Clin Orthop Relat Res*. 1989; (240): 129-136.
- [36] Conrad E.U., Gretch D.R., Obermeyer K.R., Moogk M.S., Sayers M., Wilson J.J., Strong D.M. Transmission of the hepatitis-c virus by tissue transplantation. *J Bone Joint Surg Am*. 1995; 77(2): 214-224.
- [37] O'Sullivan E.D., Battle R.K., Zahra S., Keating J.F., Marson L.P., Turner D.M. allosensitization Following Bone graft. *Am J Transplant*. 2017; 17(8): 2207-2211. doi: 10.1111/ajt.14231.
- [38] Piaia M., Bub C.B., Succì G.M., Torres M., Costa T.H., Pinheiro F.C., Napimoga M.H. Hla-typing analysis following allogeneic bone grafting for sinus lifting. *Cell Tissue Bank*. 2017; 18(1): 75-81. doi: 10.1007/s10561-016-9594-1. 28. Mosconi g., Baraldi O., Fantinati c., panicali l.,
- [39] Veronesi M., Cappuccilli M.L. et al. donor-specific anti- Hla antibodies after bone-graft transplantation. Impact on a subsequent renal transplantation: a case report. *Transplant Proc*. 2009; 41(4): 1138-1141.
- [40] Ward W.G., Gautreaux M.D., Lippert D.C.2nd, Boles c. HLA sensitization and allograft bone graft incorporation. *Clin Orthop Relat Res*. 2008; 466(8): 1837-1848. doi: 10.1007/s11999-008-0294-4.
- [41] Quattlebaum J.B., Mellonig J.T., Hensel N.F. Antigenicity of freeze-dried cortical bone allograft in human periodontal osseous defects. *J Periodontol*. 1988; 59(6): 394-397.
- [42] Reikerås O., Reinholt F.P., Zinöcker S., Shegarfi H., Rolstad B. Healing of long-term frozen orthotopic bone allografts is not affected by MHC differences between donor and recipient. *Clin Orthop Relat Res*. 2011; 469(5): 1479-1486. doi: 10.1007/s11999-011-1796-z.
- [43] Alt V., Bitschnau A., Böhner F., Heerich K.E., Magesin E., Sewing A. et al. effects of gentamicin and gentamicin – Rgd coatings on bone ingrowth and biocompatibility of cementless joint prostheses: an experimental study in rabbits. *Acta Biomater*. 2011; 7(3): 1274-1280. doi: 10.1016/j.actbio.2010.11.012.
- [44] Heppert V., Wagner Ch., glatzel U., Wentzensen A. Prinzipien der operative-chirurgischen Therapie der Osteitis. *Trauma Berufskrankh*. 2002; 4(3): 321-328.
- [45] Luther C., Unger K., Heppert V., Simon R., Hitzgrath C., Germann G., Sauerbier M. Chronic osteitis of the lower extremities. an interdisciplinary treatment concept. *Unfallchirurg*. 2010; 113(5): 386-393. (in german). doi: 10.1007/s00113-009-1709-8.
- [46] Chang Y., Shih H.-N., Chen D. W., Lee M. S., Ueng S. W. N., Hsieh P.-H. The concentration of antibiotic in fresh-frozen bone graft // *J Bone Joint Surg [Br]* 2010; 92-B: 1471-4.

Н. Д. Батпенoв¹, R. Shnattler², А. А. Белокобыльoв¹, Е. К. Раймагамбетoв¹, К. Б. Тажин¹

¹НИИ травматологии и ортопедии МЗ РК, Астана, Казахстан,

²Университетский медицинский центр Гиссена, Гиссенский университет Ю. фон Либиха, Гиссен, Германия

АЛЛОТРАНСПЛАНТАЦИЯНЫҢ ӘРТҮРЛІ ӘДІСТЕРІ КЕҢ ПАЙДАЛАНУ

Аннотация. Қазіргі уақытта травматология және ортопедияда сүйек кемістіктерін алмастыру үшін сүйек трансплантаттары кең пайдаланады, осы әдістің тиімділігі күмән тудырмайды. Сүйек трансплантаттарын пайдалануды талап ететін негізгі ортопедиялық бағыттар – бұл ірі буындарды ревизиялық және күрделі эндопротездеу, онкоортопедия. Қолданылатын материалдарға едәуір жоғары талаптар қойылады, олардың ішінде мыналарды атап кетуге болады: қолданылатын материал тек сүйек көлемін физикалық түрде толтырып қана қоймай, остеоиндукциялық қасиеттерге ие болу керек, сонымен қатар инфекциялық аурулардың берілу мүмкіндігін болғызбау қажет. «Алтын стандарт» деп танылған кемшіліксіз материал – аутосүйек, бірақ белгілі бір жағдайларға байланысты оның пайдалануы шектелген және қазіргі уақытта аллотрансплантацияның әртүрлі әдістері кең енгізілуде.

Түйін сөздер: сүйек кемістіктерін алмастыру, жаңамүздатылған аллотрансплантаттар.

Н. Д. Батпенoв¹, R. Shnattler², А. А. Белокобыльoв¹, Е. К. Раймагамбетoв¹, К. Б. Тажин¹

¹НИИ травматологии и ортопедии МЗ РК, Астана, Казахстан,

²Университетский медицинский центр Гиссена, Гиссенский университет Ю. фон Либиха, Гиссен, Германия

ПРИМЕНЕНИЕ СВЕЖЕЗАМОРОЖЕННЫХ АЛЛОТРАНСПЛАНТАТОВ В ОРТОПЕДИИ

Аннотация. В настоящее время в травматологии и ортопедии для замещения костных дефектов широко используются костные трансплантаты, не вызывает сомнений и эффективность данного метода. Основные ортопедические направления, требующие привлечения костных трансплантатов это ревизионное и сложное эндопротезирование крупных суставов, онкоортопедия. Требования к применяемым материалам довольно высокие, среди них можно выделить следующие: применяемый материал должен не только физически заполнять объем кости, но и обладать остеоиндуктивными свойствами, при этом необходимо исключить возможность передачи инфекционных заболеваний. Идеальным материалом, который принят за «золотой стандарт» является аутокость, но в силу определенных условий его использование ограничено и в настоящее время широко внедряются различные методы аллотрансплантации.

Ключевые слова: костная аллотрансплантация, свежемороженые аллотрансплантаты, эндопротезирование.