REPORTS OF THE NATIONAL ACADEMY OF SCIENCES OF THE REPUBLIC OF KAZAKHSTAN
ISSN 2224-5227 **https://doi.org/10.32014/2018.2518-1483.24**
Volume 6, Number 322 (2018), 40 – 44

UDC 612.425+611.428

G. A. Demchenko, N. A. Akhmetbayeva

(RSE «Institute of Human and Animal Physiology» MES RK, Almaty)
Current work was carried out with financial support under the framework of scientific projectAP05133060
georgiidemchenko@mail.ru

ADRENERGIC INNERVATION OF LYMPHATIC NODES FROM VARIOUS BODY REGIONS IN YOUNG AND MATURE ANIMALS

Annotation. Adrenergic innervation in the tissues of cervical, mesenteric and popliteal lymph nodes in rats of different age groups (2-45 days and 10-11 months) was studied using the specific fluorescence-microscopic method of visualization of catecholamines. Adrenergic innervation in lymph nodes of rats is present from the first days of life and in the process of postnatal ontogenesis it tends to develop and gradually become more complex and is fully formed by the 20th-30th day from birth.
Keywords: lymph nodes, adrenergic nervous apparatus.

The lymphatic system takes an active part in maintaining homeostasis at the cellular, tissue and organism levels, carrying out the barrier function in the interaction of the organism with the external and internal environment [1, 2]. The most important component of the lymphatic system is the lymph nodes. Lymph nodes have a complex structure;lymphoid tissue takes up to 80% of the volume of the node. Under the capsule, there is a subcapsular sinus, and the lymphoid tissue is permeated with numerous cerebral sinuses, whose width is 20-60 micrometers.Endothelial cells lining the sinuses have many appendages and, together with the reticular cells, form a complex three-dimensional network in the lumen of the sinuses through which lymph flows. The capsule covering the lymph nodes consists mainly of connective tissue elements, between which there are bundles of smooth muscle cells oriented for different directions [3]. It is established that the myocytes of the capsule of the lymph nodes rhythmically synchronously contract, leading to an increase in the intra-node pressure and the displacement of lymph from the node into the enduring lymphatic vessels [4].

The age-related changes in the morphofunctional state of lymphatic vessels and nodes are discussed in a number of scientific works [5, 6, 7]. In adulthood, lymph nodes, performing immune-drainage-detoxification functions in the body, undergo some structural changes [6, 8].

We have shown the formation of the morphophysiological function of the lymphatic system in postnatal ontogenesis [9, 10, 11]. A sharp decrease in the transport function of the lymph nodes in conditions of its denervation has been shown [12]. The current research is devoted to the study of adrenergic innervation apparatus of the lymph nodes at different stages of postnatal ontogenesis, that is, from the first day of life of the rats and up to the adult period.

In the available literature, there is no information about the adrenergic innervation apparatus in the structure of the lymph nodes in different age periods of life.

The aim of the study was to study the adrenergic innervation of the lymph nodes of different topographic and anatomical localization in young and mature animals.

Materials and methods. The experiment was performed on white rats with allocation to groups aged 2-45 days and 10-11 months. In each group there were 15 animals (n-30), which were given free access to water and food. All experiments with animals were carried out in strict accordance with the rules developed and approved by the local ethical commission of Kazakh National Medical University named after S.D. Asfendiyarov, as well as in accordance with the rules and requirements stipulated by the 1986 directive of European Parliament and set out in the "Guidelines for the care and use of laboratory

animals". For the study, mesenteric, cervical, popliteal lymph nodes were taken. To study the adrenergic nervous apparatus of the lymph nodes, a specific histochemical fluorescence-microscopic method for the detection of catecholamines in tissues using the glyoxalic acid was used which was initially developed by Falk and later modified by V. A. Govyrin [13]. Total vascular sections and cryostatic sections of lymph nodes 20 micrometers thick were prepared. The preparations were incubated in a 2% solution of glyoxalic acid prepared on phosphate buffer with pH of 7.2. Then the sections were dried under a warm air stream and thermostated at 100° C, followed by clarification and fixation with a 5% solution of polystyrene dissolved in xylene. Lymph node preparations were studied using a Vision 300 (Australia) fluorescence microscope with a camera.

Results and discussion. Both in young and mature rats, lymph node preparations were studied, prepared from the concave side, where the lymph node gate is located, through which the incoming arteries and nerves pass, and veins and vascular lymphatic vessels exit. Our study showed that in rats aged 2-7 days in lymph nodes single nerve fibers with weak fluorescence were observed, which shows a low content of catecholamines in them. At the end of these single growing neural fibers fluorescent varicose thickenings are more clearly detected.In rats aged 7-15 days, along with the presence of single nerve fibers, the appearance and formation of nerve plexuses occurs, but already from 12-15 days in the tissues of the lymph node there is a further development of the adrenergic apparatus, an increase in the number of nerve fibers, the formation of multiple plexuses between them and the appearance of varicose thickenings along the entire length. The density of adrenergic innervation in the lymph nodes, a characteristic of adult animals, appears already from 25-30 days from birth (Figures. 1a, 2a, 3a).

Adrenergic nerve plexuses are formed in the wall of arterial vessels entering the cervical lymph node (Figures 1a, b). The figures show that in the wall of the blood vessel of the cervical lymph node the large-plexed nerve plexuses consisting of thick nerve bundles branch into several thin single nerve fibers. Along the length of single nerve fibers,the distribution of varicose extensioncanbe observed, which give a more intense glow, characteristic for catecholamines. The area of the lymph node gates has the highest adrenergic innervation.

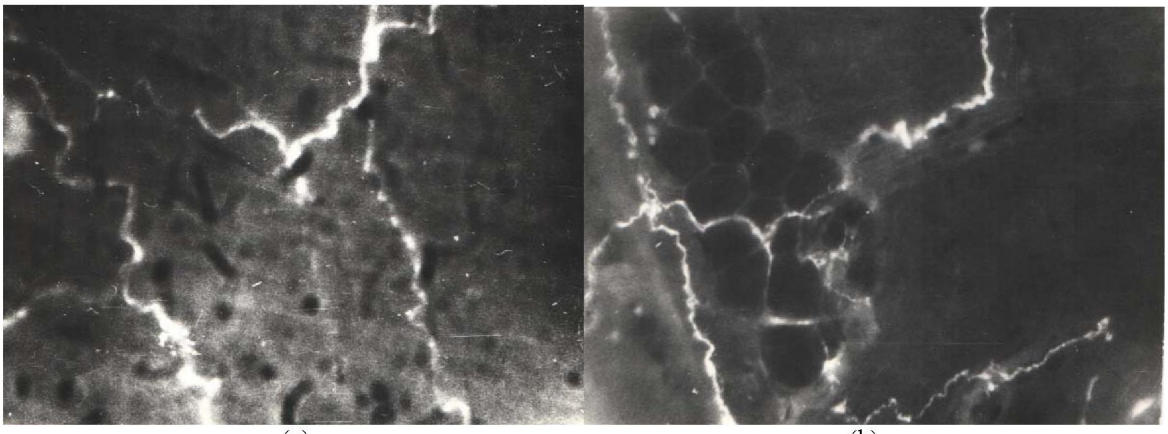

(a) (b)

Figure 1 (a) -Total preparation. Adrenergic nerve fibers in the artery wall in the area of the cervical lymph node gates in rats aged 3-4 months. (b).Total preparation. Adrenergic nerve fibers in the artery wall in the area of the cervical lymph node gates in rats aged 11 months. Lens 30, Oc. 6,3x

Figures 2a, b show a cryostatic section of the blood vessel feeding the mesenteric lymph node (Figures 2a, b). It was noted that the brightly fluorescent catecholamine-containing nerve fibers are distributed in the medio-adventitial layer. Such nerve fibers leave the vessel wall and penetrate into the surrounding connective tissue of the lymph node.

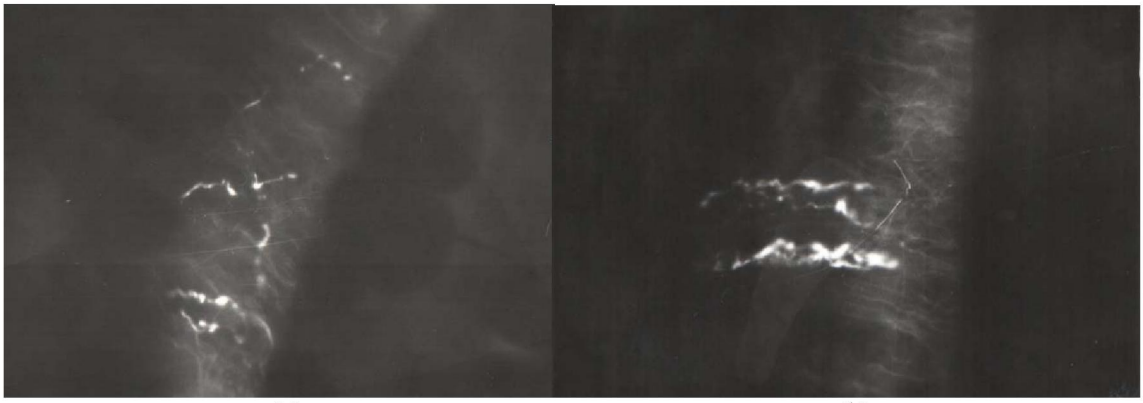

(a) (b)

Figure 2(a) - Cryostatic section of the artery in the area of the mesenteric lymph node gates of a rat aged 12 days.
(b).Cryostatic section of the artery in the area of the mesenteric lymph node gates of a rat aged 10.5 months.
Lens 30, Oc. 6,3x

On the transverse section (Figures 3a, b) in the area of the gates of the popliteal lymph node in the wall of the blood vessels, individual adrenergic neural bundles have a bright fluorescence. Regularly located along the nerve fiber, small and large varicose thickenings give a more vivid fluorescence than the nerve fiber itself.

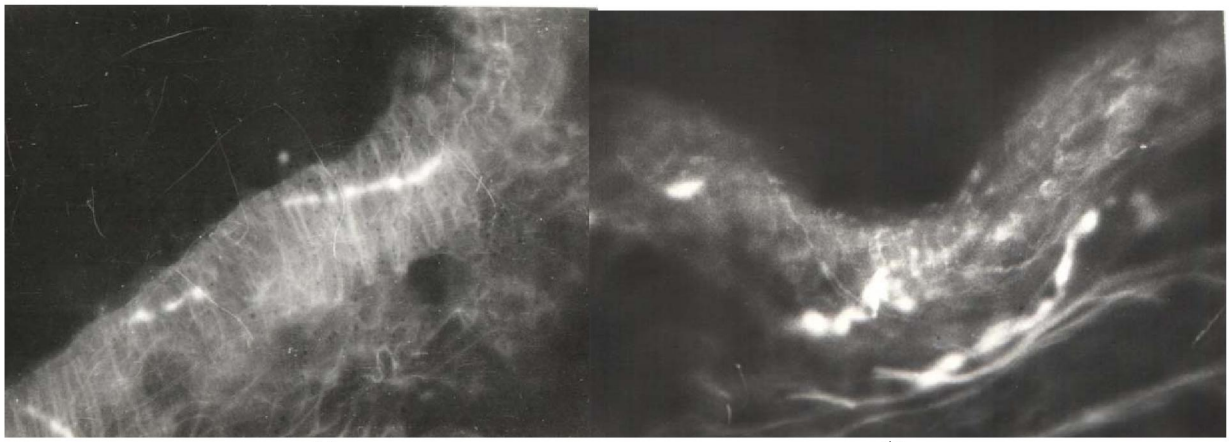

(a) (b)

Figure 3(a) - Cryostatic section of artery in the area of the popliteal lymph node gates of a rat aged3 days.
(b).Cryostatic section of artery in the area of the popliteal lymph node gates of a rat aged10 months.
Lens 30, Oc. 6,3x

The reason for our attention to the area of the lymph node gates was that this region proved to have a higher adrenergic innervation. As we have noticed, on the preparations of the lymph node gates, separate adrenergic nerve fibers were distributed between the trabeculae, leaving the vascular wall. Initially, these nerve fibers serve as the adrenergic innervation apparatus of the wall of blood vessels, and only the individual single thin nerve fibers, separated from the intra-walled vascular nerve plexus, are distributed among the connective tissue of the trabeculae of the lymph node. It is known that in the area of the gates in the capsule of the lymph node there is the greatest number of smooth muscle myocytes. It used to be considered that in the vascular wall the varicose thickenings of the terminal sections of adrenergic axons, in the region of which catecholamines are being released, are at certain definite distances from the smooth muscle cells [14]. The adrenergic nervous apparatus provides motor transmission of signals from the nerve fiber to the smooth muscles, that is, it participates in the realization of vasomotor efferent signaling [15].

Consequently, the presence of an adrenergic innervation apparatus and smooth muscle cells in the tissue of the lymph nodes affects its contractile function. In the age groups studied by us (2-45 days and 10-11 months), differences in the ratio of the structural components of the lymph nodes are possible. We have considered the qualitative side of adrenergic innervation of the lymph nodes. In both month-old and mature rats, the adrenergic innervation is characterized by the presence of multiple nerve fibers that form plexuses with regularly located varicose extensions along the entire length of the nerve fiber. The presence of adrenergic nerve fibers in the capsule of the lymph node is shown, where there is an accumulation of smooth muscle cells. It is known that adrenergic mediators have a distant effect on smooth muscle cells; the distance between them corresponds to 200 nm. Regular varicose thickenings have a brighter fluorescence, which may indicate a high content of catecholamines in them. Such varicose thickenings are considered to be depots of catecholamines [16].

Thus, on the basis of the data obtained by us, it can be asserted that, starting from the first days of postnatal ontogenesis, the adrenergic apparatus continues to form in the tissues of lymph nodes, and is fully formed by the 25-30 day after the birth of rats, and it is logical to affirm that the lymph nodes have an adrenergic vasomotor innervation, which influences their function.

REFERENCES

[1] Borodin Ju. I., Skljanova H. A., Izranov V. A., Semenjuk A. B. Nejromediatornoe obespechenie organov immunnoj sistemy vuslovijah intoksikacii benzpirenom // Bjull. jeksperim. biol. imed., 1992, N2. P.166-168.

[2] Borodin Ju. I. Limfologija kak integrativnaja mediko-biologicheskaja nauka // Vestnik limfologii, 2011, №2. P. 4–7.

[3] Sapin M.R., Borzjak Je.I., Vneorgannye puti transporta limfy. -M., Medicina, 1982. -263 p.

[4] Lobov G.I., Orlov R.S. Kletochnye mehanizmy reguljacii transporta limfy // Ros. fiziol. zhurn. 1995. T.81. № 6. P. 19-28

[5] Pigolkin Ju. I., Zolotenkova G. V. Vozrastnye izmenenija nervnogo apparata sosudov spinnogo mozga // Bukovins'kij Medichnij Visnik, 2013, T.17, №3 (67), ch. 1. P. 122-124.

[6] Gorchakova O. V., Gorchakov V. N. Strukturnaja organizacija limfouzlov raznoj funkcional'noj specializacii na jetape pozdnego ontogeneza // Biologicheskie nauki, 2015, №7 (38), ch. 2. P. 74-76.

[7] Petrenko V. M., Petrenko E. V. Mehanika kompensatornyh processov v jeksperimental'nom razvitii parenhimy limfouzlov // Mezhdunarodnyj zhurnal prikladnyh i fundamental'nyh issledovanij, 2013, № 10-2. P. 164-166.

[8] Borodin Ju.I. Teoreticheskie predposylki profilakticheskoj limfologii i zdorov'e cheloveka v Sibiri // Bjull. SO RAMN, 2008, №5 (133). P. 14-17.

[9] Bulekbayeva L. Je., Akhmetbayeva N. A., Erlan A. E. Vlijanie ishemii raznoj prodolzhitel'nosti na adrenergicheskij nervnyj apparat podkolennogo limfaticheskogo uzla krysy // Doklady AN RK, 2010, №5. P. 72-75. **https://doi.org/10.32014/2018.2518-1483**

[10] Akhmetbayeva N. A., Bulekbayeva L. Je., Demchenko G.A. Adrenergicheskij nervnyj apparat podzheludochnoj zhelezy pri ostrom pankreatite // Doklady NAN RK, 2013, №6. P. 68-72. **https://doi.org/10.32014/2018.2518-1483**

[11] Bulekbayeva L. Je., Akhmetbayeva N. A. Razvitie simpaticheskih vlijanij na limfotok v postnatal'nom ontogeneze u sobak // Zhurn. jevoljuc. biohim. i fiziol., 1982, T.18, N2. P.140-143.

[12] Chevagina N. N. Morfofunkcional'nye izmenenija v limfaticheskih uzlah posle denervacii. Dis. kand. Novosibirsk, 1971.

[13] Govyrin V. A. Adaptacionno-troficheskaja funkcija sosudistyh nervov // Razvitie nauchnogo nasledija akad. L.A. Orbelli. L.: Nauka, 1982. P. 169-181.

[14] Bülbring E, Tomita T.Catecholamine action on smooth muscle // PharmacolRev. 1987, N39 (1), P. 49-96.

[15] Medić, B. The role of autonomic control in cardiovascular system: summary of basic principles // Medical Youth, 2016, N67, V.1. P. 14-18.

[16] Akhmetbayeva N.A. Morfo-fiziologicheskaja harakteristika grudnogo limfaticheskogo protoka sobak v postnatal'nom ontogeneze. Aftoref.dis. ... kand. biol. nauk. Alma-Ata, 1982. 28p.

Г.А. Демченко, Н.А. Ахметбаева

(РГП «Институт физиологии человека и животных» МОН РК, г. Алматы)
Работа выполнена при финансовый поддержке в рамках научного проектаAP05133060

АДРЕНЕРГИЧЕСКАЯ ИННЕРВАЦИЯ ЛИМФАТИЧЕСКИХ УЗЛОВ ИЗ РАЗНЫХ РЕГИОНОВ ТЕЛА У МОЛОДЫХ И ЗРЕЛЫХ ЖИВОТНЫХ

Аннотация. С помощью специфического флуоресцентно-микроскопического метода визуализации катехоламинов изучалась адренергическая иннервация в ткани шейного, брыжеечного и подколенного лимфоузлов у крыс разных возрастных групп (2-45 дней до 11 месяцев). Показано наличие адренергической иннервации в лимфатических узлах с первых дней жизни, и в процессе постнатального онтогенеза она развивается и усложняется, и полностью формируется к 20-30 дню от рождения.
Ключевые слова: лимфатические узлы, адренергический нервный аппарат

Г.А. Демченко, Н.А. Ахметбаева

ҚР БҒМ «Адам және жанурлар физиологиясы институты» РМК, Алматы қ.
Жұмыс AP05133060 ғылыми жоба аясында қаржылық қолдау негізінде орындалды.

ЖАС ЖӘНЕ ЕРЕСЕК ЖАНУАРЛАР ДЕНЕСІНІҢ ӘРТҮРЛІ АЙМАҚТАРЫНДАҒЫ ЛИМФА ТҮЙІНДЕРІНІҢ АДРЕНЕРГЕТИКАЛЫҚ ИННЕРВАЦИЯСЫ

Аннотация. Арнаулы флуоресцентты-микроскопиялық әдістеме қолдану арқылы 2-45 күндік және 10-11 айлық егеуқұйрықтардың мойын, аш шек, тізе асты бездерінің адренергиялық нерв аппараты зерттелді. Зерттеу нәтижесінде егеуқұйрықтардың лимфа бездерінде туғанынан бірінші күннен бастап, адренергиялық нерв талшықтары пайда болып, пост-наталдық онтогенез процессінде күрделеніп 20-30 күнде толық дамығаны көрсетілген.
Түйін сөздер: лимфа бездері, адренергиялық нерв аппараты.

Information about authors:

Demchenko G. A., Akhmetbayeva N. A. - RSE «Institute of Human and Animal Physiology» MES RK, Almaty. Current work was carried out with financial support under the framework of scientific projectAP05133060.